

MODULE 3 L05

Internal Heart Anatomy

Dr. Lisa Brinn

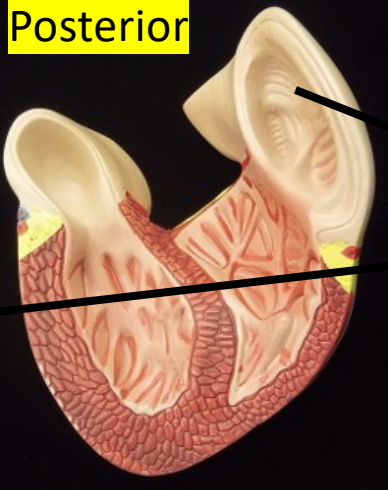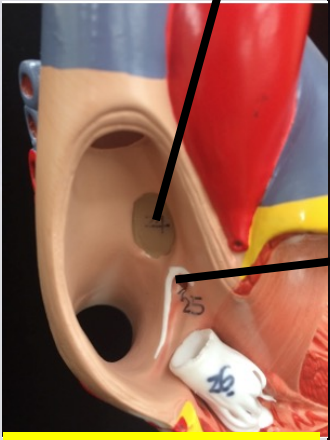
lbrinn@fiu.edu



5. Internal Heart Anatomy

Fossa ovalis

Posterior



Pectinate muscle

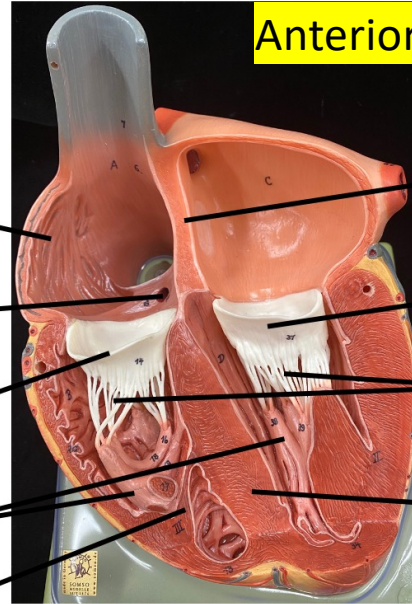
Opening of coronary sinus

Right atrioventricular valve

Papillary muscle

Moderator band

Anterior

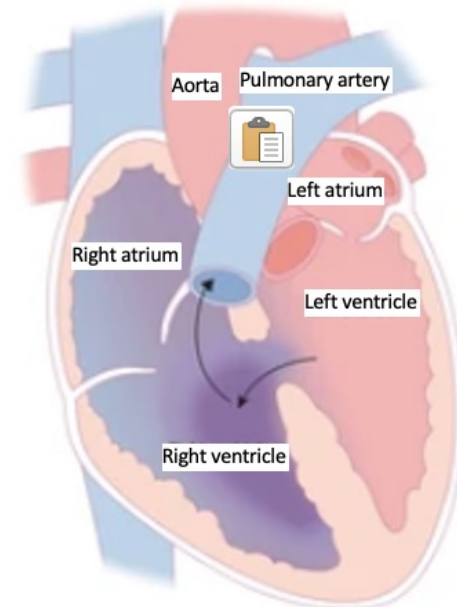


Interatrial septum

Left atrioventricular valve

Chordae tendineae

Interventricular septum

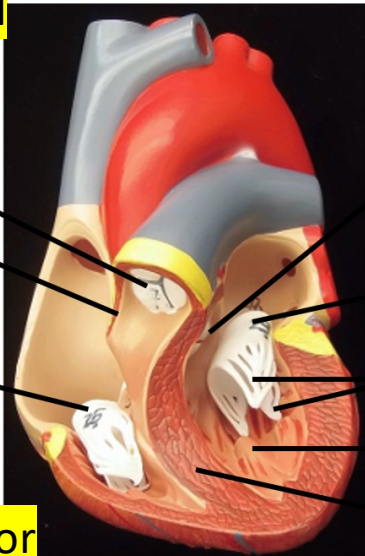


Pulmonary valve

Interatrial septum

Right atrioventricular valve

Anterior



Aortic valve

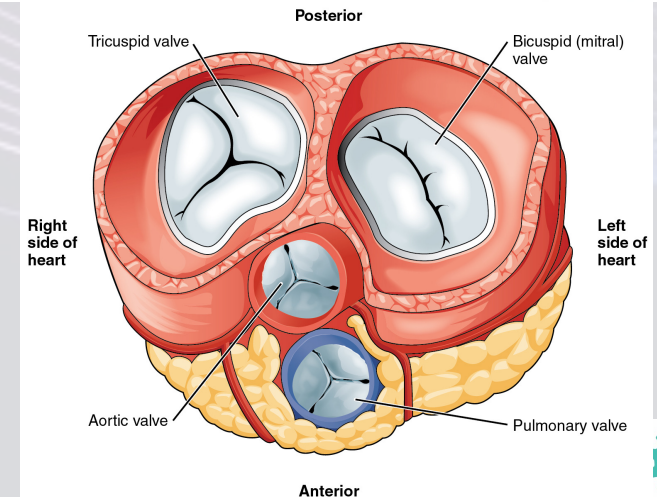
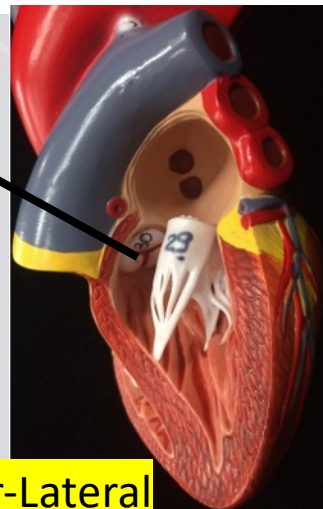
Left atrioventricular valve

Chordae tendineae

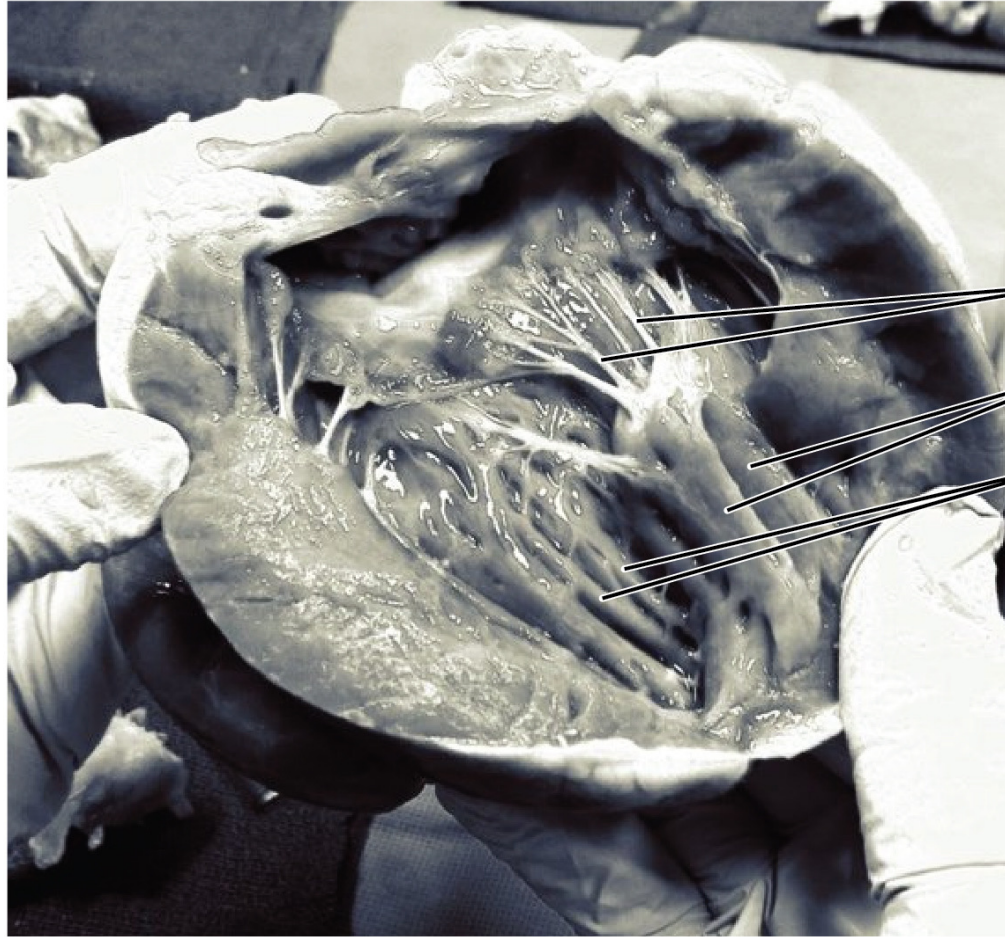Papillary muscle

Interventricular septum

Anterior-Lateral



Chordae Tendineae and Papillary Muscles



Chordae tendineae

Papillary muscles

Trabeculae carneae